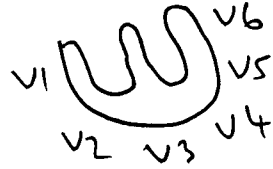

# ECG NOTES




1 P wave. 3-5 small squares

Arrhythmias: AF by far the commonest




## 2 Axis

Rt Axis deviation



Lung conditions

Lt Axis deviation




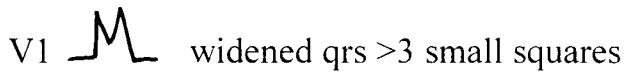
Usually LBBB Ischaemia occ LVH

3 QRS up to 3 small squares

## Bundle Branch Blocks

RBBB Makes interpretation difficult e.g. T waves inverted

May be harmless but could be ischaemia [if sympt present]




LBBB Indicates LV disease Ischaemia

Prevents any further interpretation of ECG

V6 widened qrs >3 small squares




QRS in RV leads S>R V1 

In LV leads R>S V6 

Q waves in LV leads up to 2mm deep and 1 mm wide..over 2mm means infarct, age cannot be determined..also normal to have small q in III [but not also in AVF and not with Rt Axis Deviation]

4 ST-T

ST either elevated or depressed

Elevated in acute myocardial injury [recent infarct]   
Anterior infarct V leads Inferior infarct III AVF

Depressed= Ischaemia



T wave inversion Normal AVR V1 III  
Ischaemia  
BBB

Digoxin...slopes downward



QT interval not more than 10 small squares



Rare things

RVH RAD R in V1 S in V6 Ts RBBB

Bifascicular block RBBB+LAD

Posterior Infarct R in V1

Wolff Parkinson White Syndrome

Delta Wave



slowed upstroke qrs